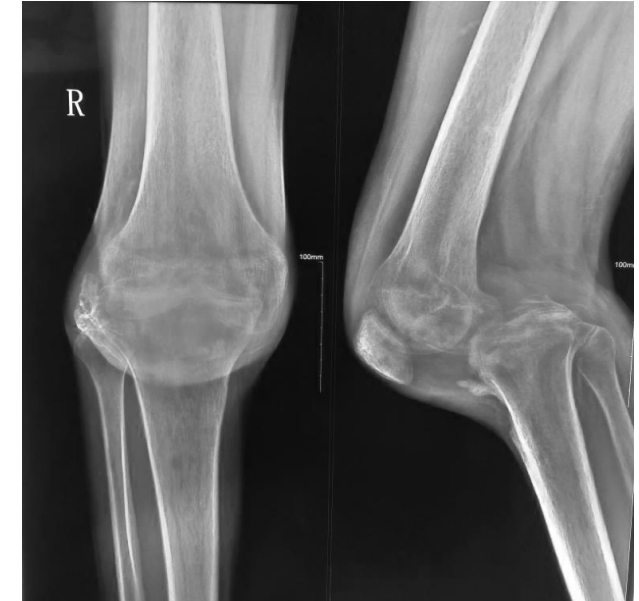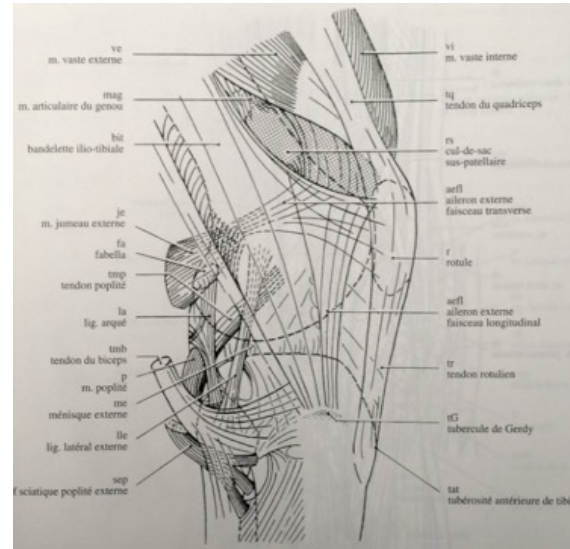

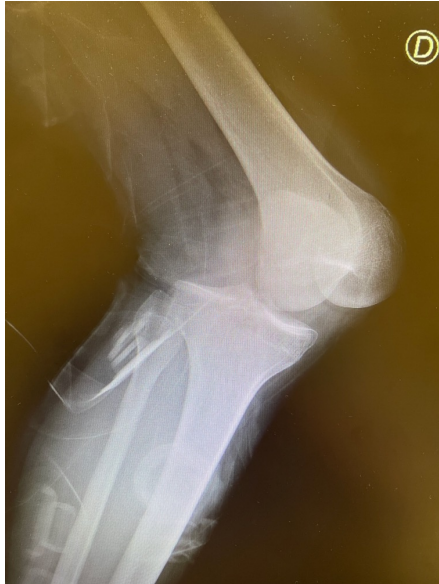
**BOTH CRUCIATE
AND POSTEO-LATERAL LESION
F-X GUNEPIN, P BOISRENOULT**



Postero-lateral injuries : an underdiagnosed lesion

Pacheco RJ, Ayre CA, Bollen SR. Posterolateral corner injuries of the knee: a serious injury commonly missed. J Bone Joint Surg Br. 2011 Feb; 93 (2) :194-7



Both cruciate and postero-lateral lesion : about 5%

LaPrade RF. Introduction and incidence of posterolateral knee injuries. In: Posterolateral knee injuries: anatomy, evaluation and treatment. New York: Thieme, 2006:1-8.

REFERENCES

LESIONS POSTERO-LATERALES du Genou de l'Adulte

S. PLAWESKI
GRENOBLE


Ph. BOISRENOULT
VERSAILLES



Symposium Lésions postéro-latérales du genou BORDEAUX 2013



<http://www.sofarthro.com/medias/show/lesions-postero-laterales-du-genou/499>



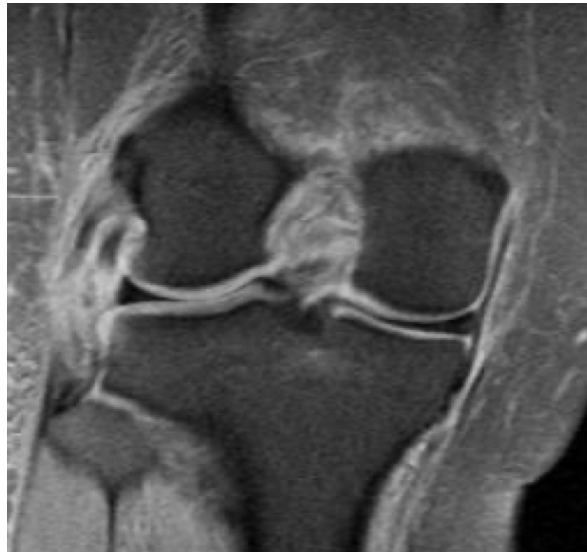POSTULATES

- Uncommon Diagnosis
- Sentinel bone lesions (fibula head)
- Common peroneal nerve = Alarm signal
- Acute < D 21
- Graft > Suture

Diagnosis

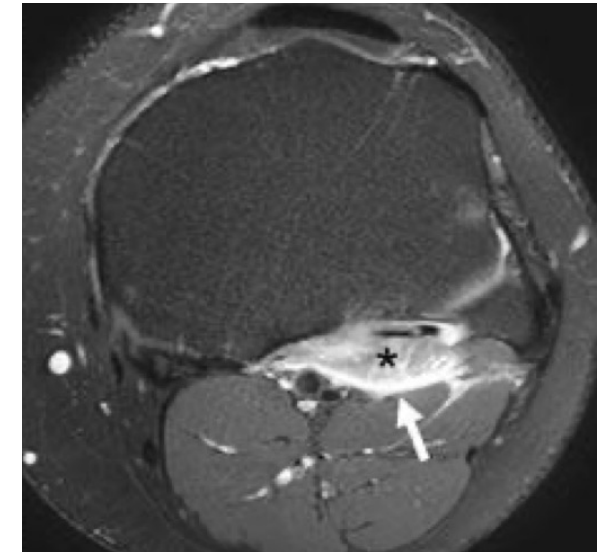
IN ACUTE

- Dislocation mechanism
- Testing under general anesthesia
- MRI



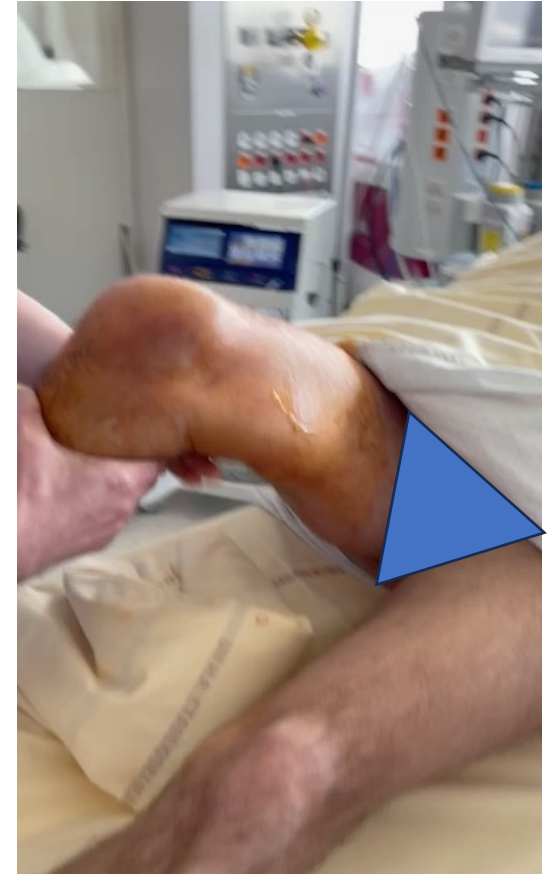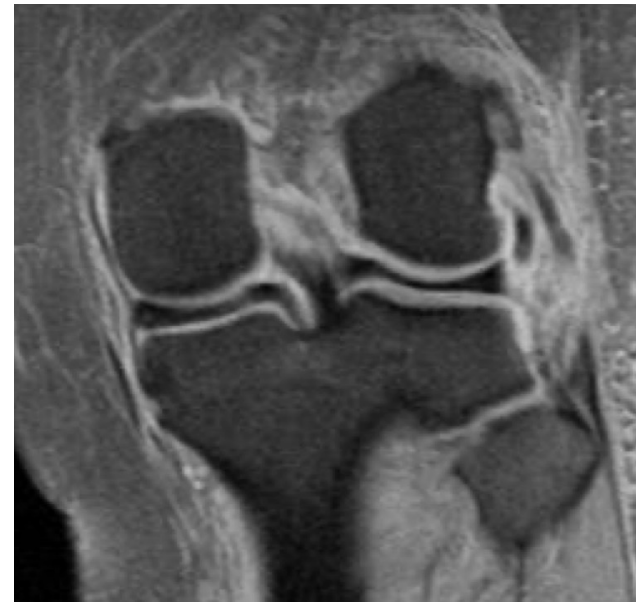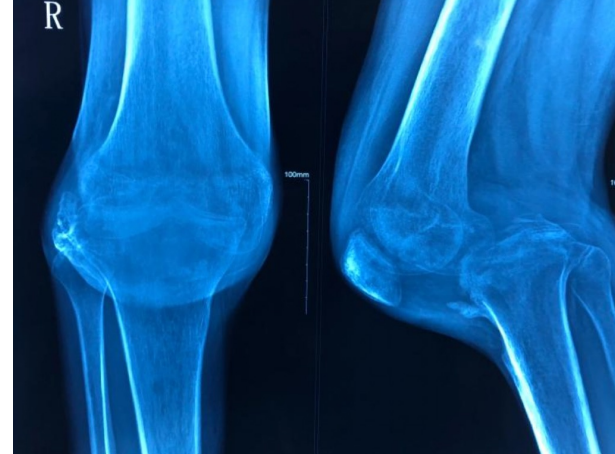
IN CHRONICLE

- Clinical testing
 - hugston test
 - lateral laxity
- stress x-ray
- MRI



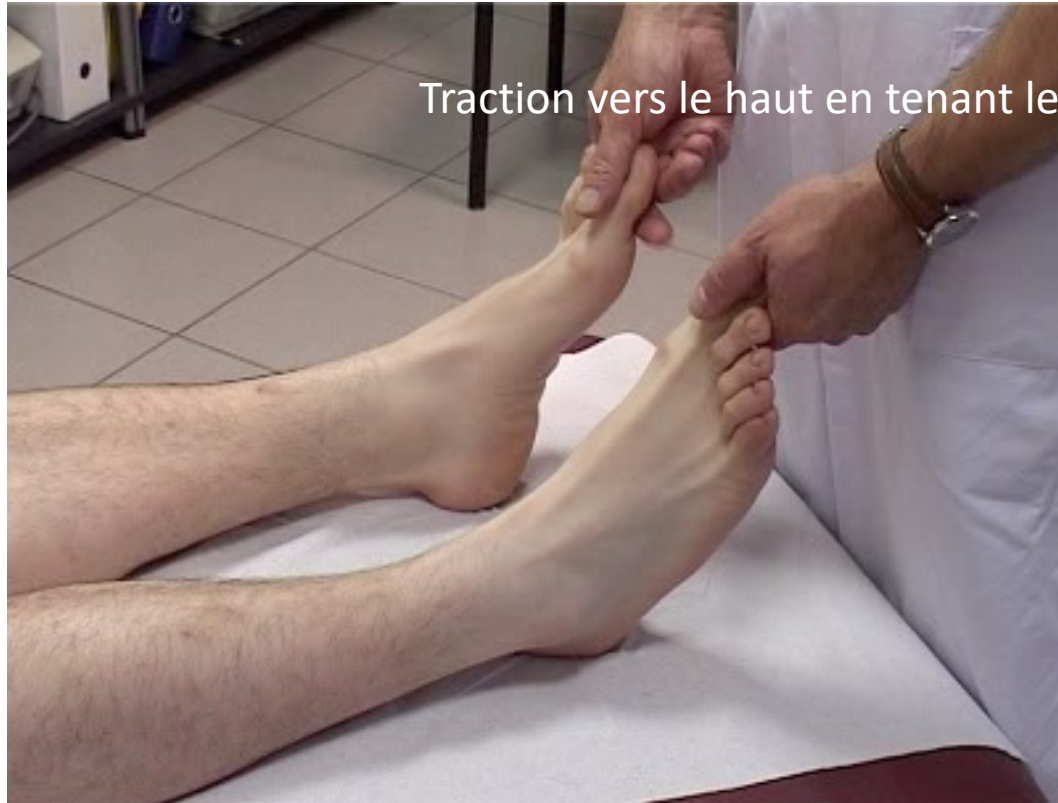Acute

- Dislocation
- Varus + internal rotation
- Indirect sign
 - Fibular nerve deficit
 - Fracture of the head of the fibula
- MRI



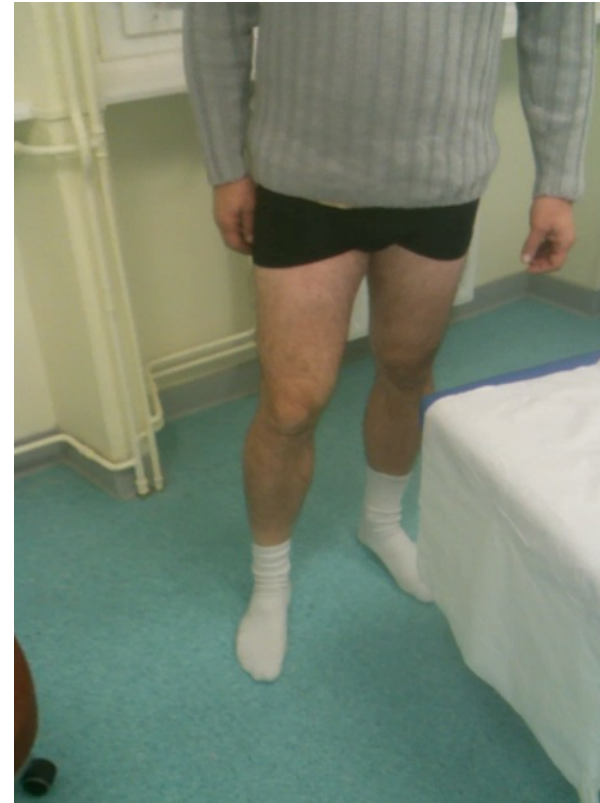CHRONICLE → PHYSICAL EXAMINATION

HUGHSTON RECURVATUM TEST

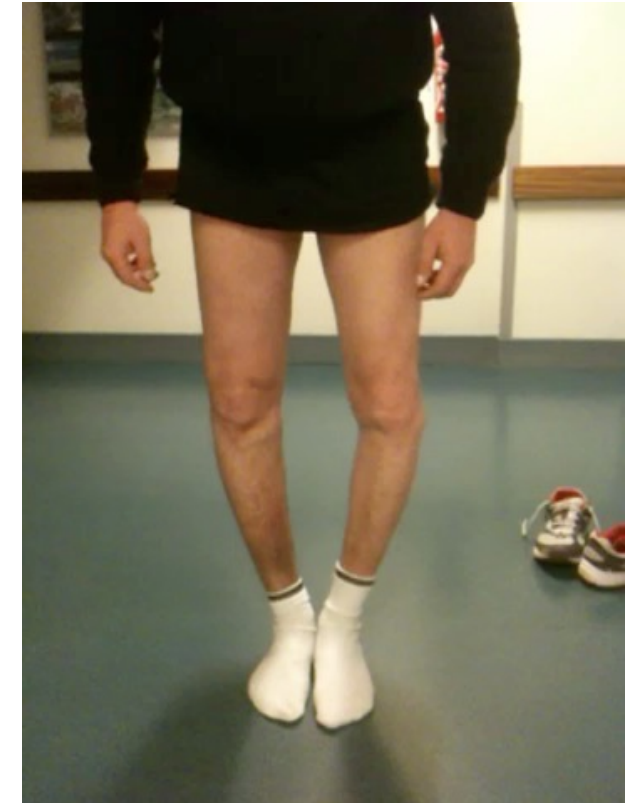

Recurvatum
External rotation

(Hughston, Clin Orthop 1980)



Weeks...

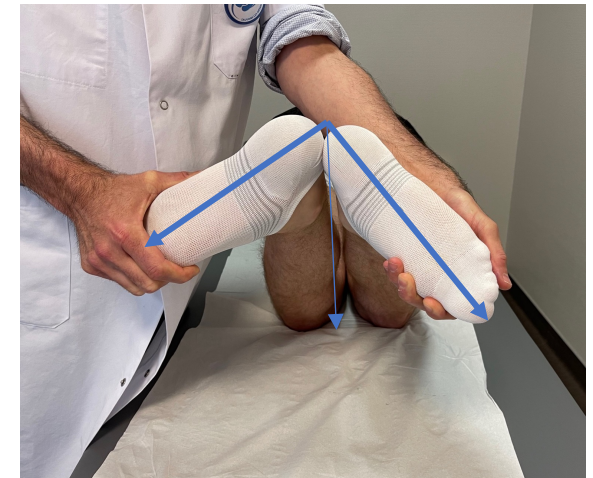
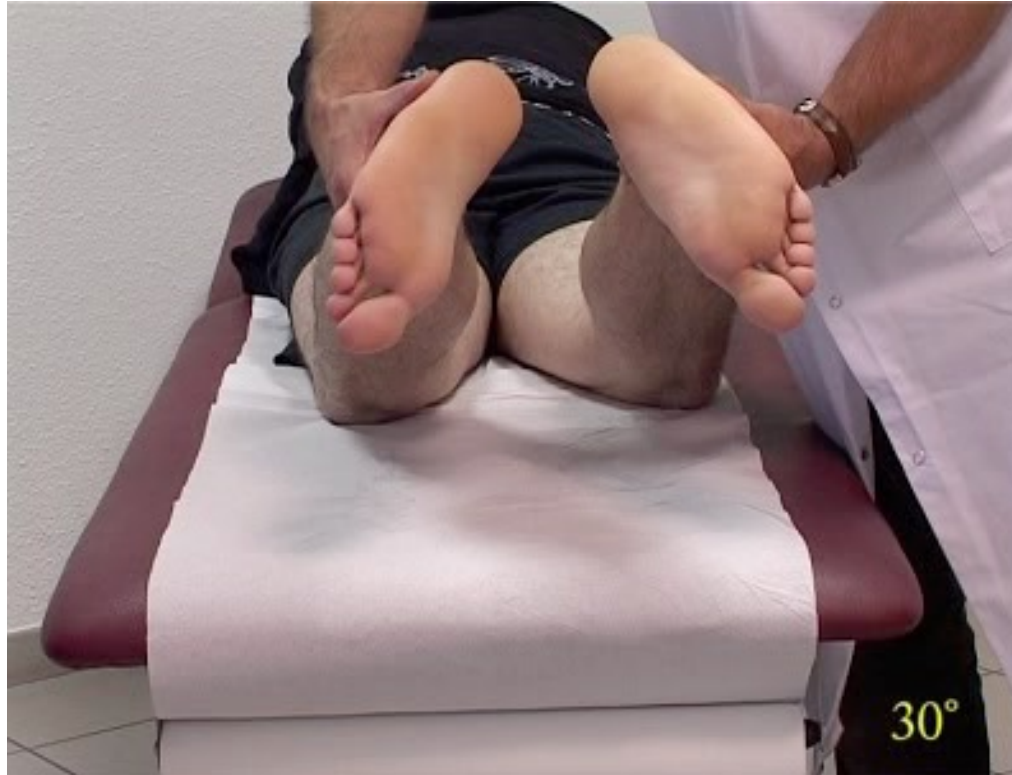
Years



DIAL TEST

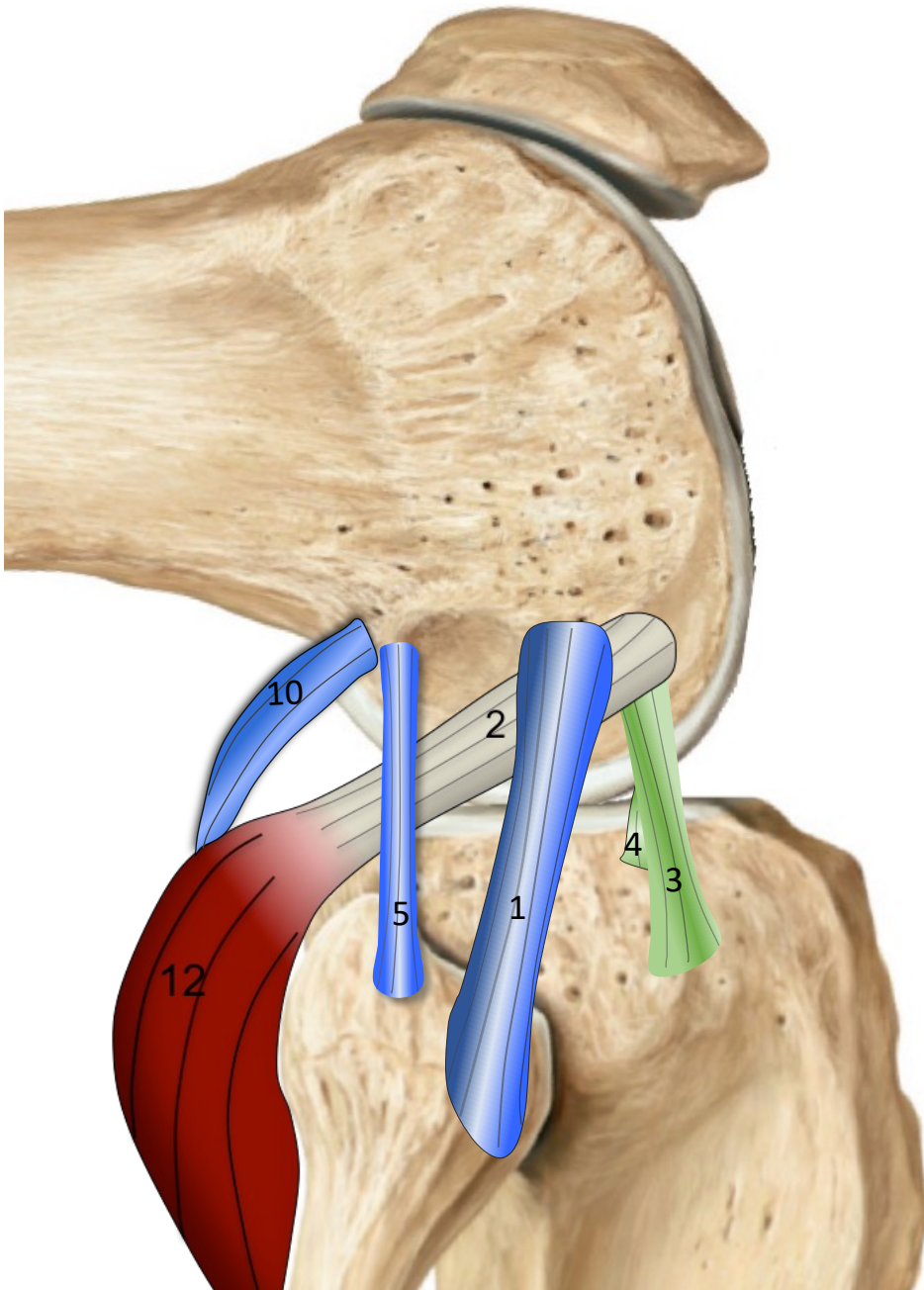
Comparison at 30° and 90°
Positive if more than 15° difference
Test + at 30° flexion:
==> Popliteus tendon
Test + at 30° and 90° flexion:
popliteus + PCL



(Larson 2001, Miller 1999, Veltri, AM J Sport Med 1996; Gollehan,1987;Groo,1988; Noyes,1993; Bleday,1998)

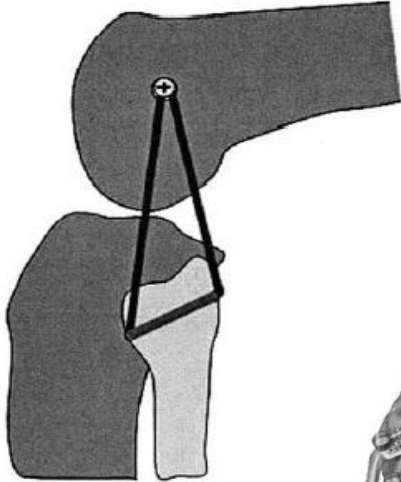
What structures should we treat?

- Valgus Control
 - ➔ FCL (1)
- Control of the rotary component
 - ➔ Popliteus tendon (2)
 - ➔ **Popliteofibular ligament (5)**

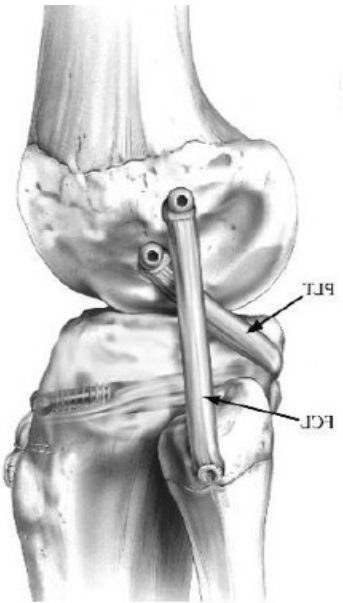
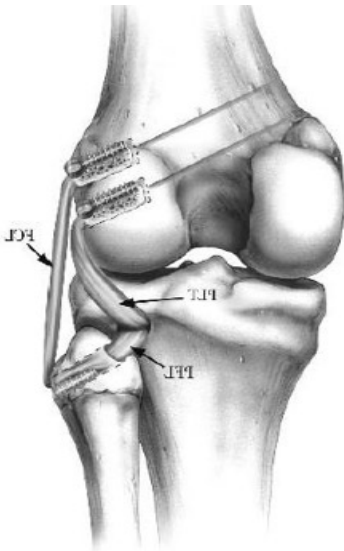


Differents techniques

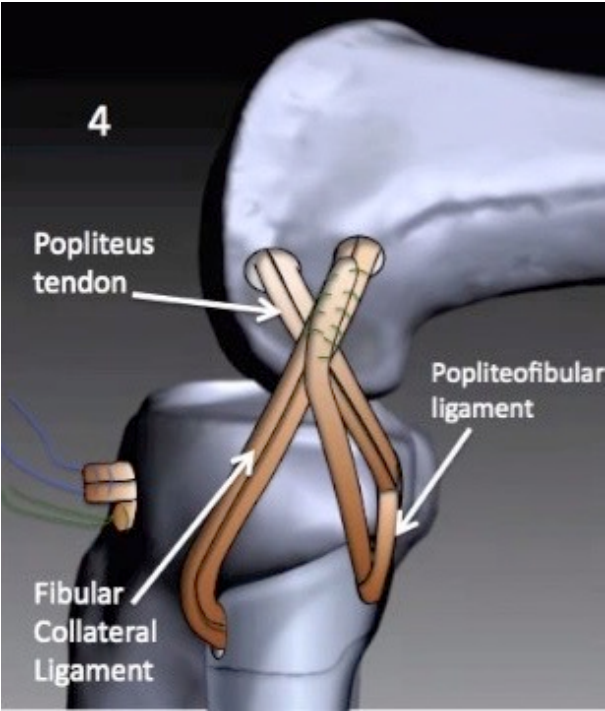
- Larson



- Laprade



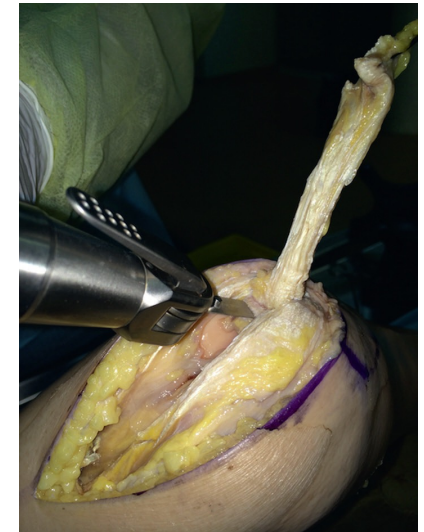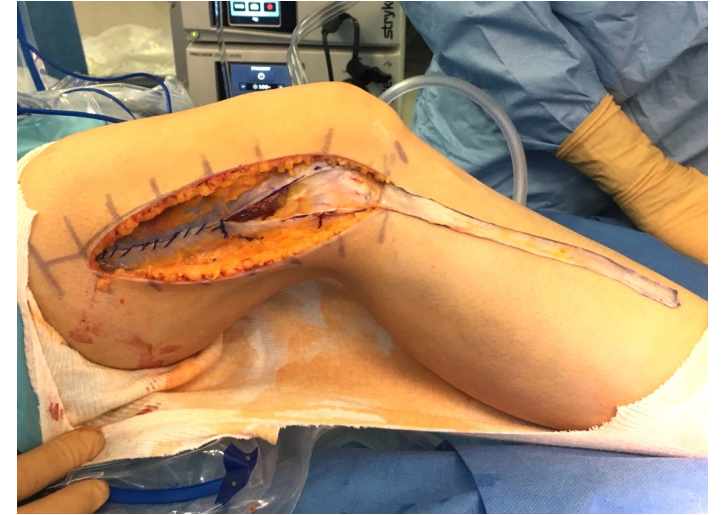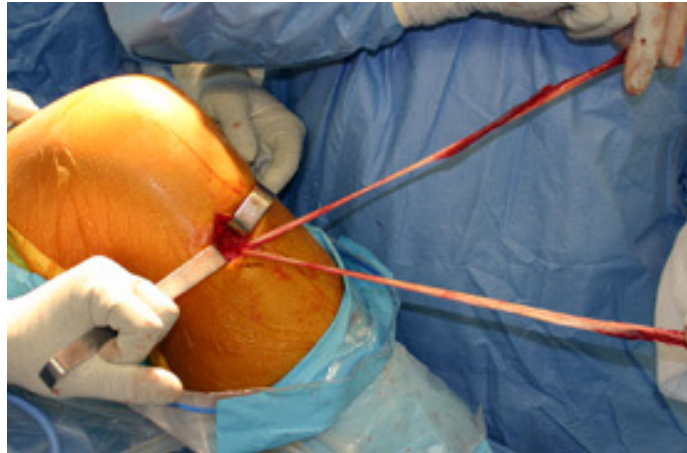
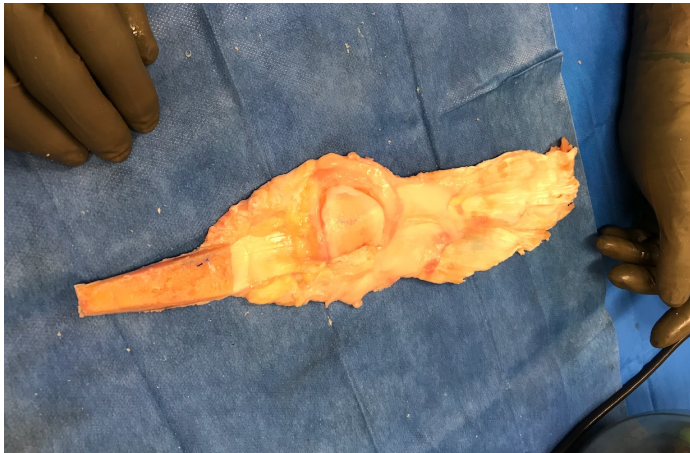
- Versailles



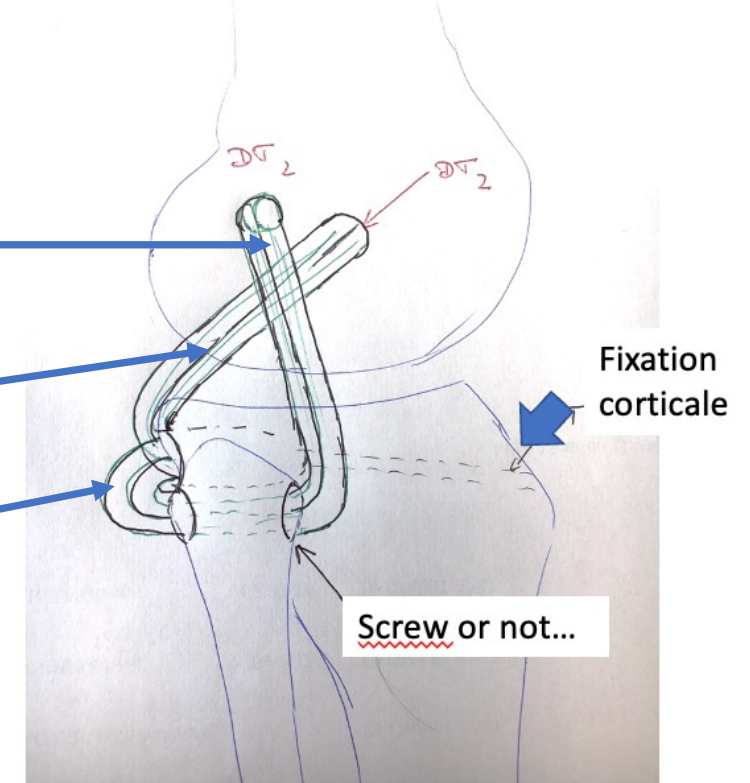
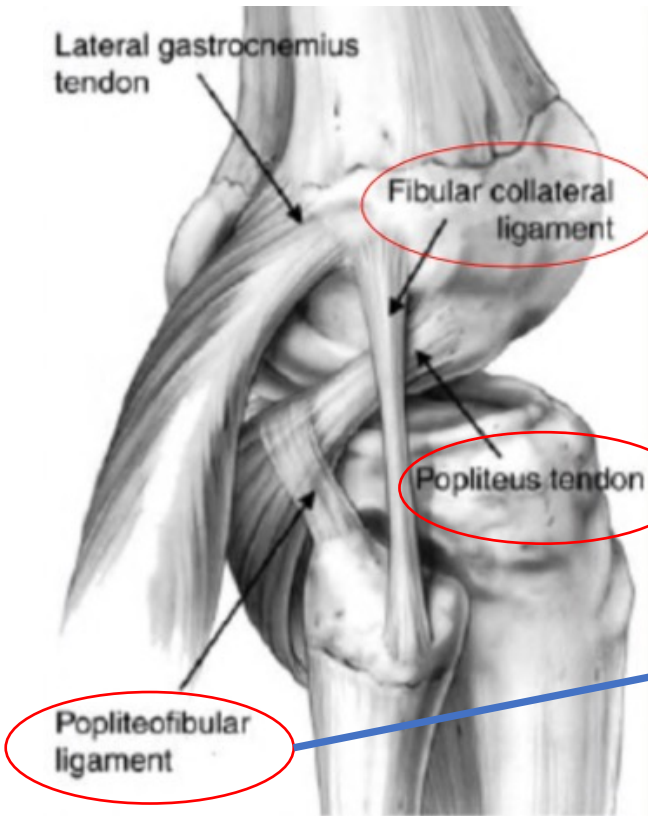
DIFFERENT GRAFT

AUTO OR ALLOGRAFT OR COMBINAISON

- ACL → fascia lata+/- Gracilis
- PCL → QT
- Ppopliteus and FCL → ST
- Or Allograft



Goals and Strategy



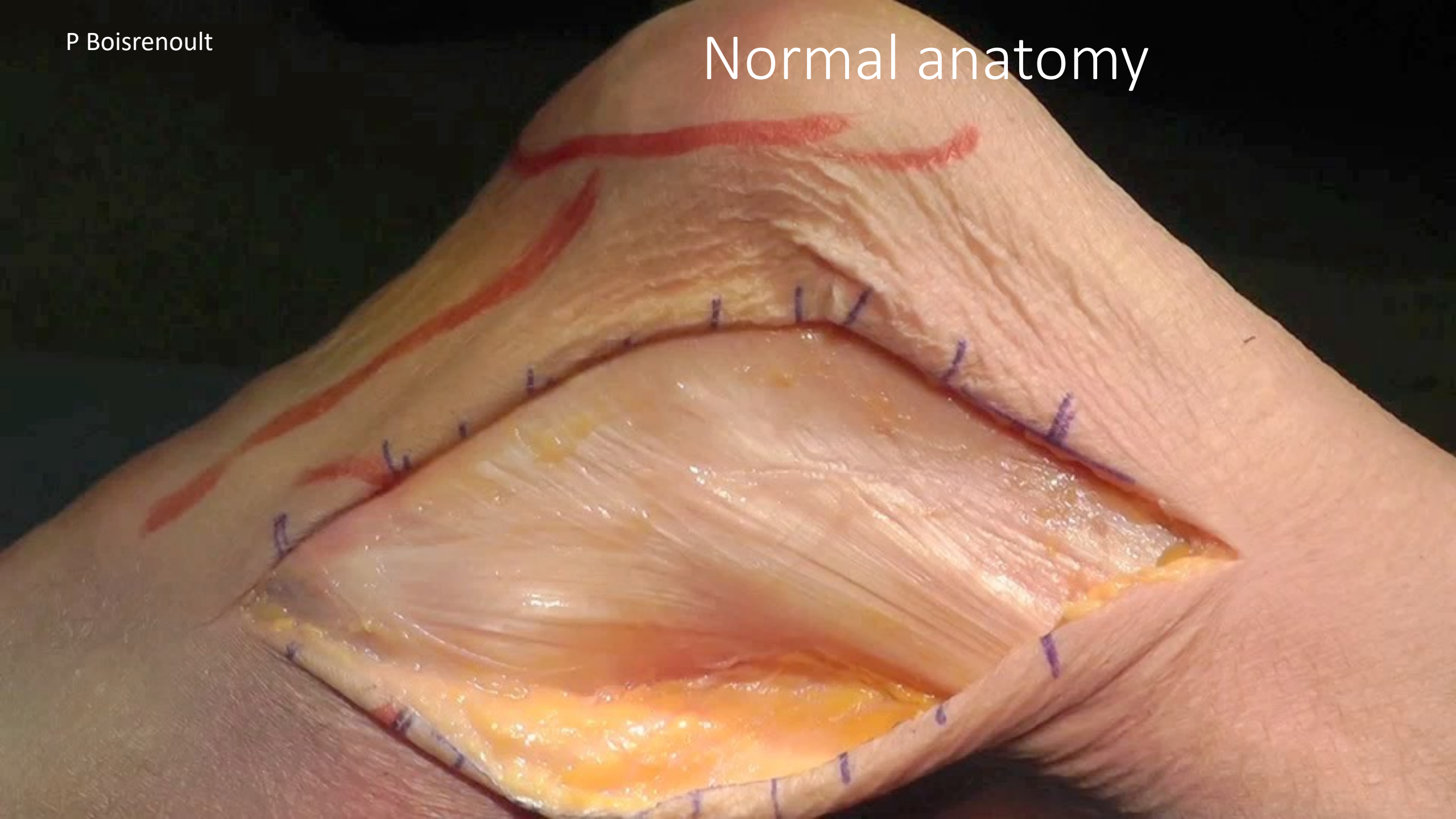
The objective is to obtain overall kinematics comparable to the healthy knee whatever the degree of flexion.

- The FCL, effective in extension
- The popliteo fibular ligament, effective in flexion

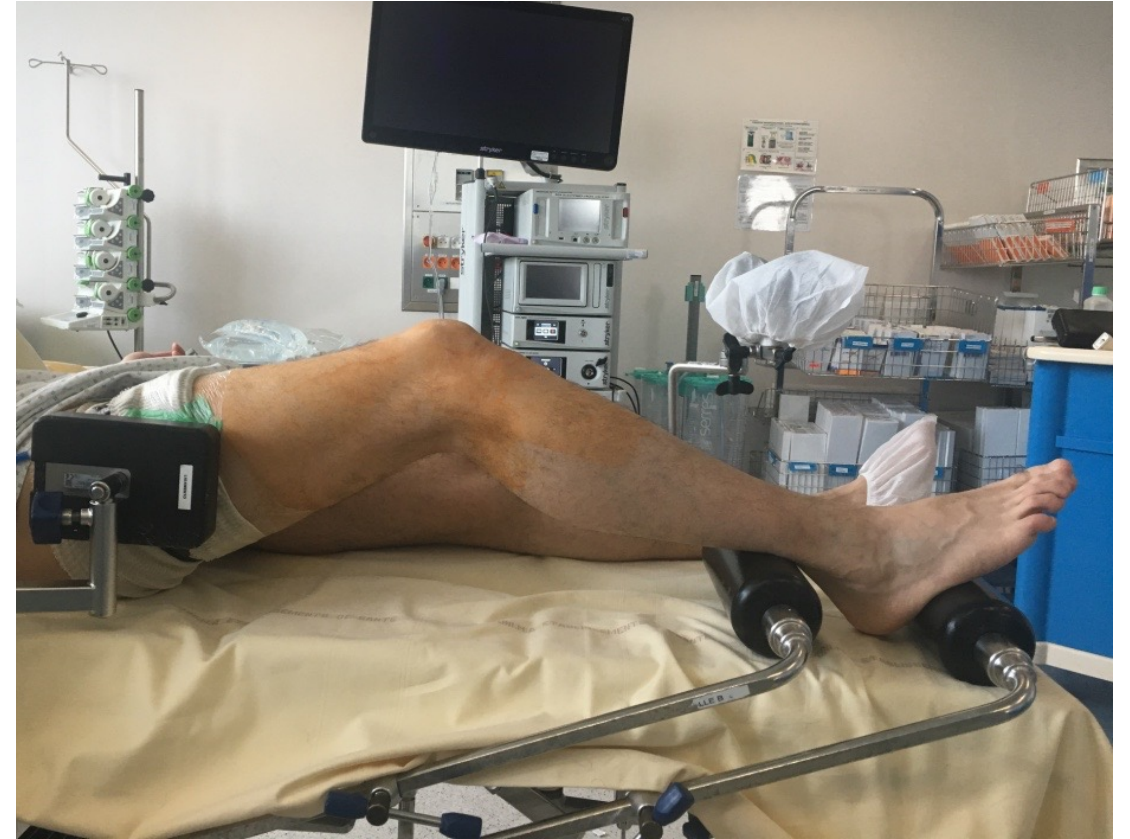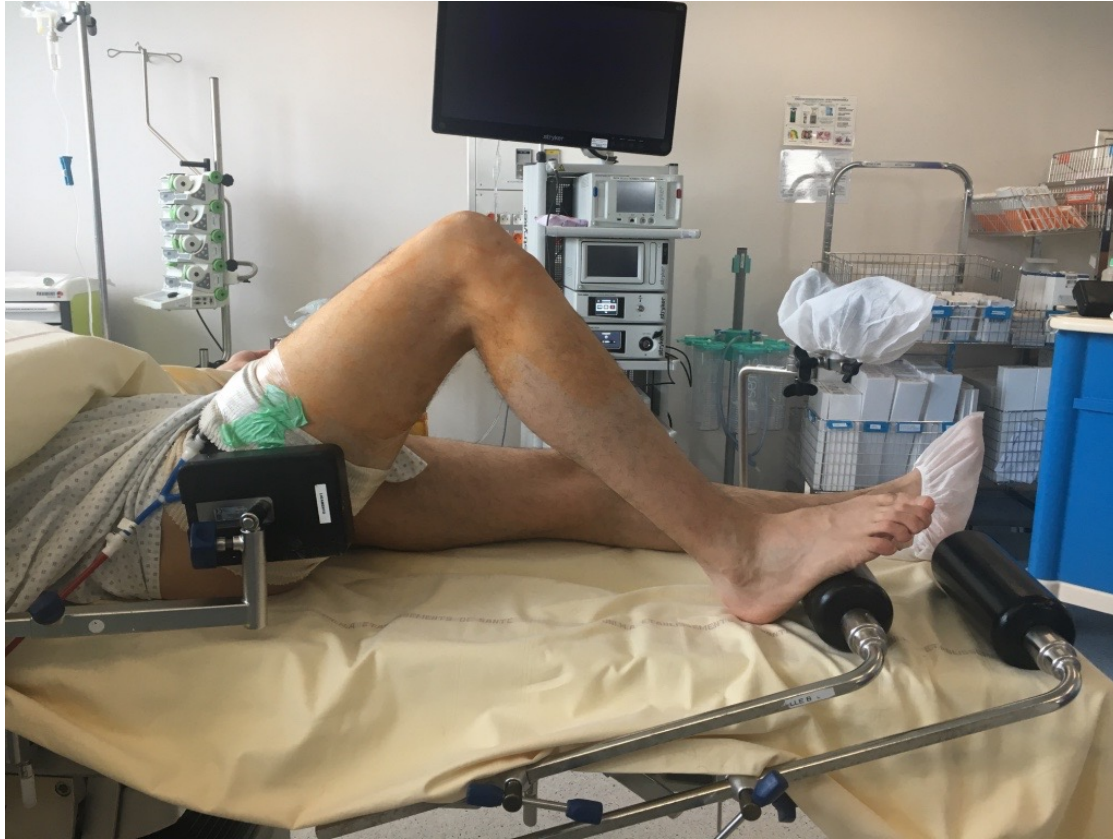SURGICAL PLAN

- Harvesting of the ST
- Lateral approach
- Opening of the fascia lata identifying the biceps
- NFC tracking
- Fibula exposure

Normal anatomy



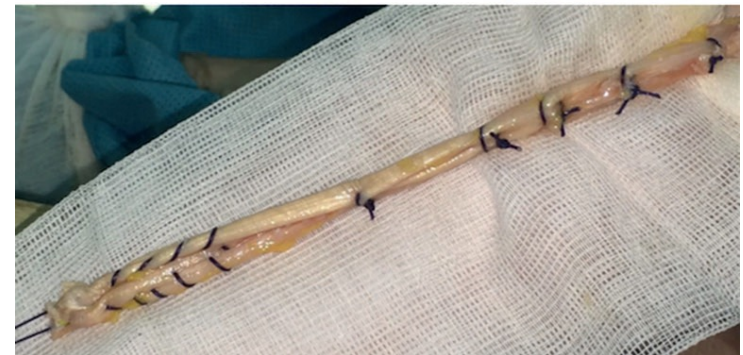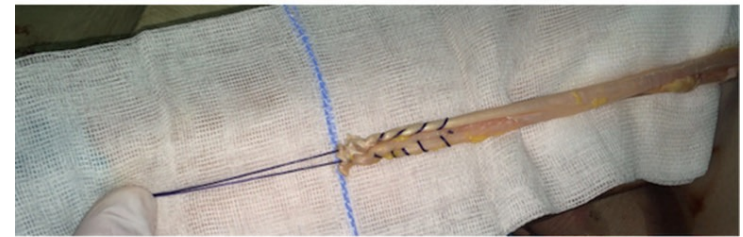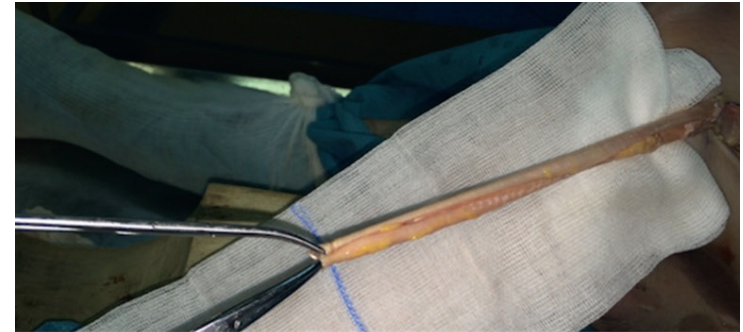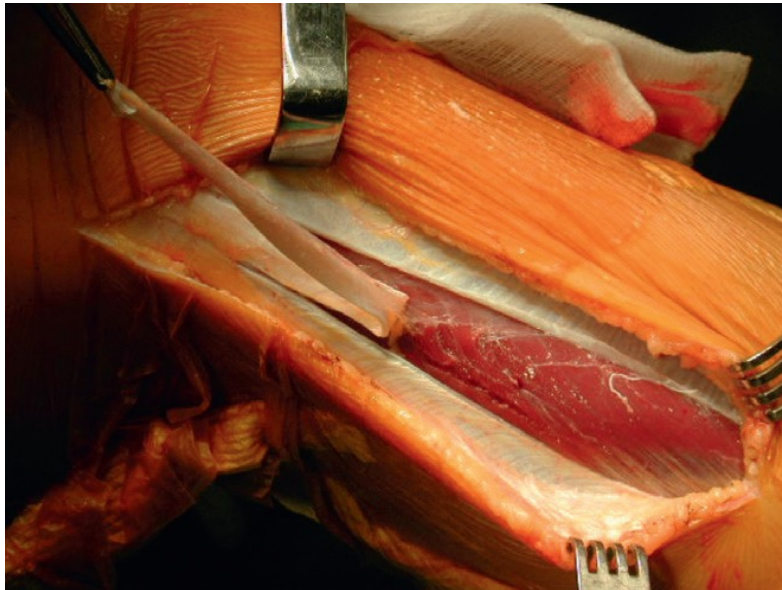
Fascia Lata = ACL + ALL with one graft



Fascia Lata

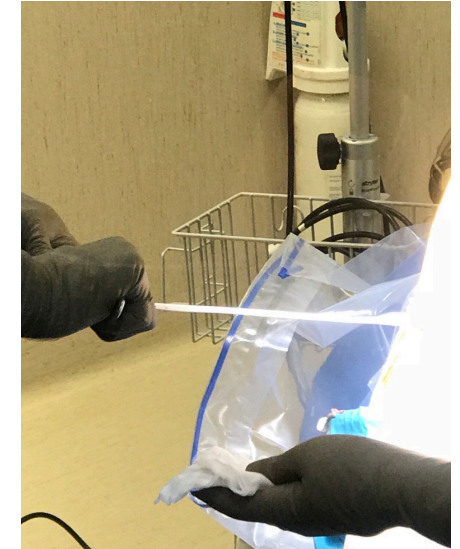
Operating technique:

- Preparation for the plasty
- Tubulization of the plasty

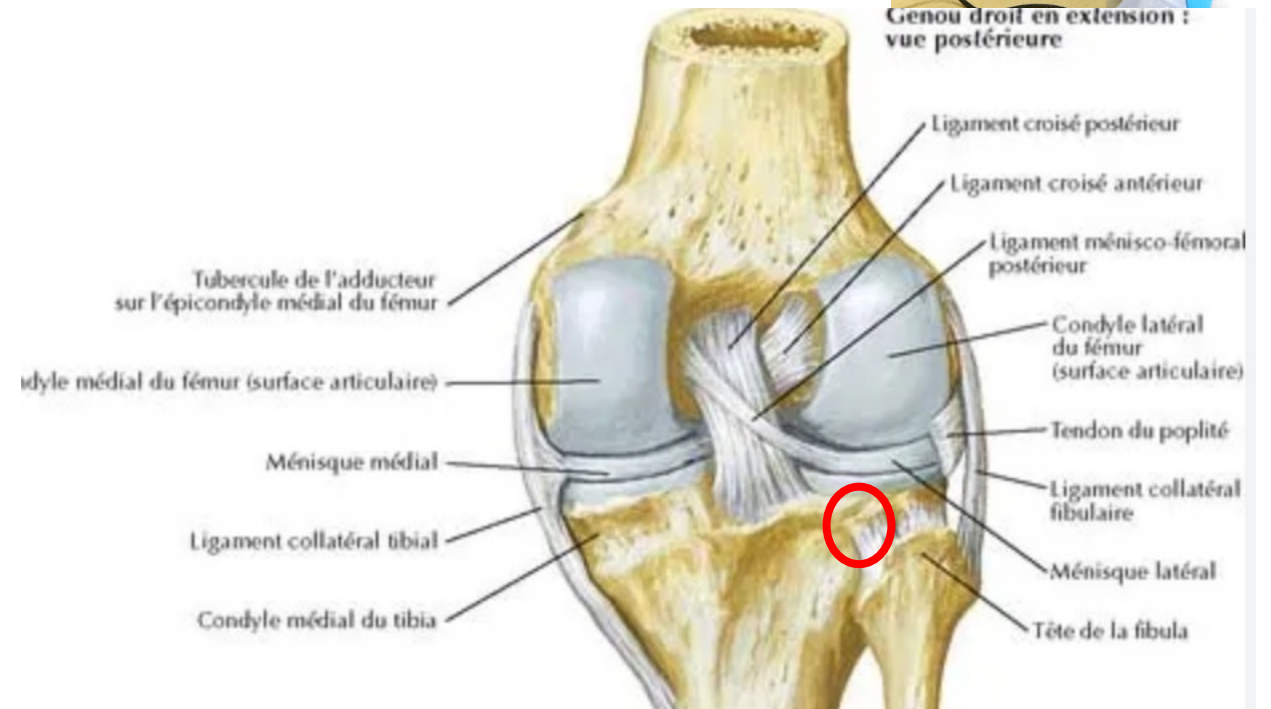


SURGICAL STEP

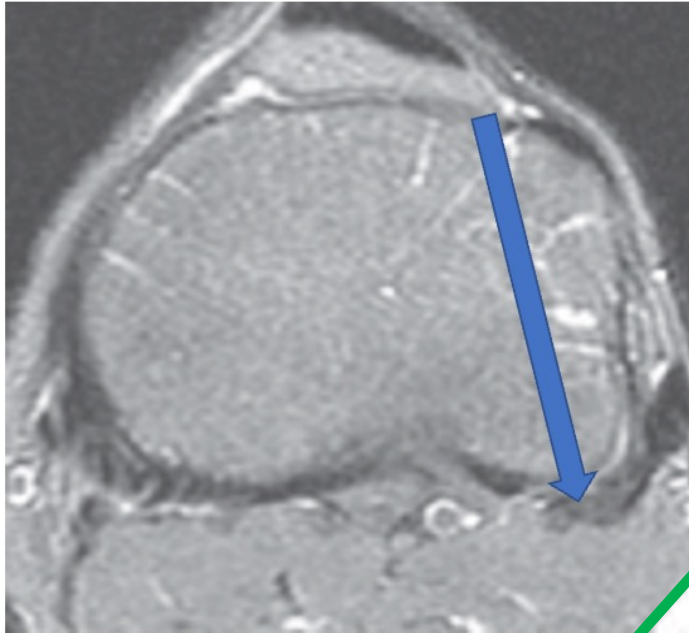
- Fibula exposure
- Identification FCI and Popliteus tendon
- Exposure of the posterolateral border of the tibial epiphysis
- **Tunnel Tibial**
- Fibular tunnel
- Femoral tunnels



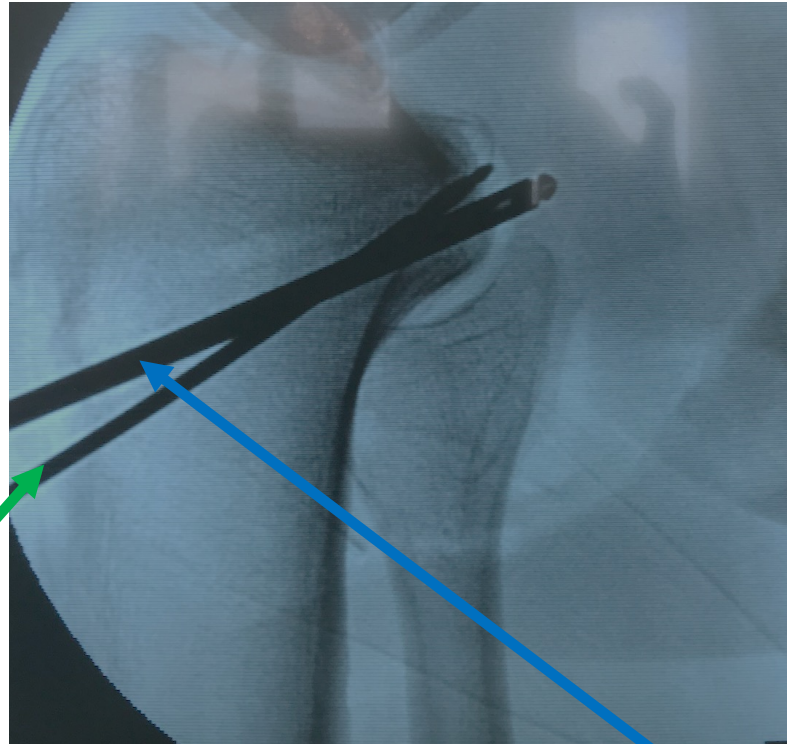
Genou droit en extension :
vue postérieure



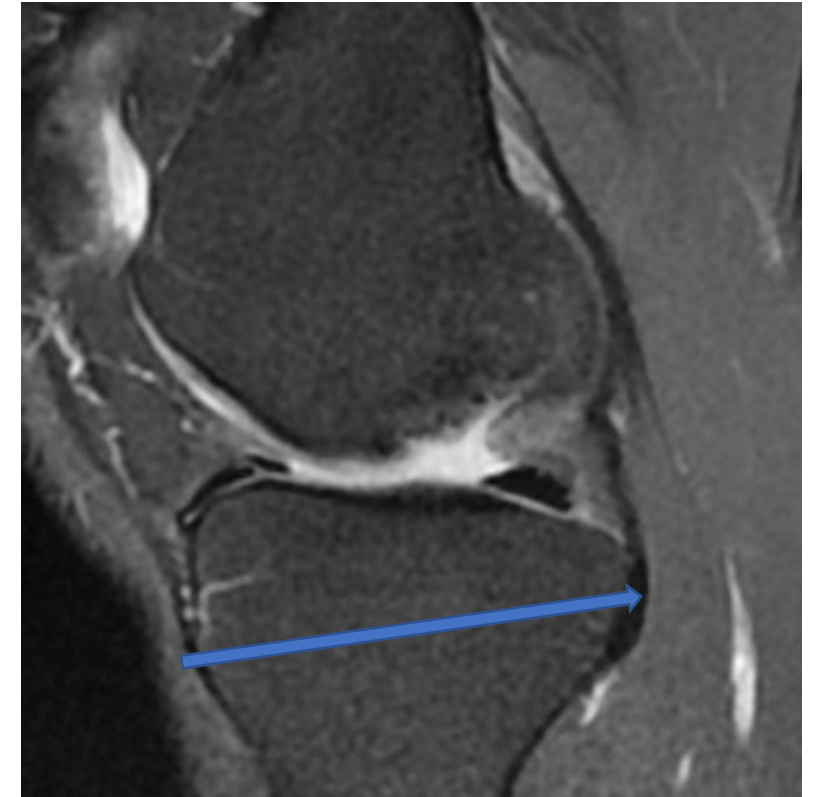FIRST TIBIAL TUNNEL WITH RETRO-DRILLING



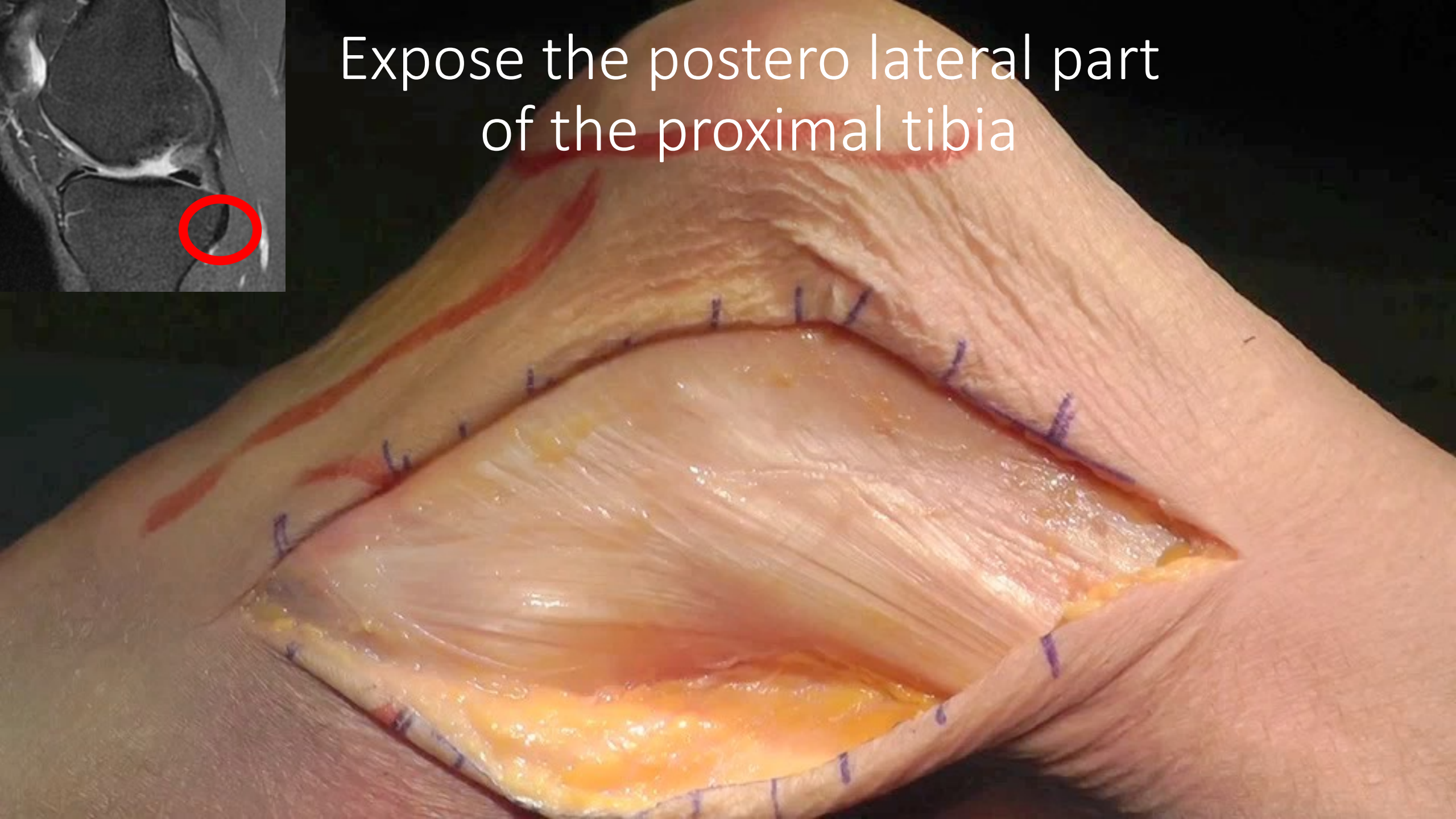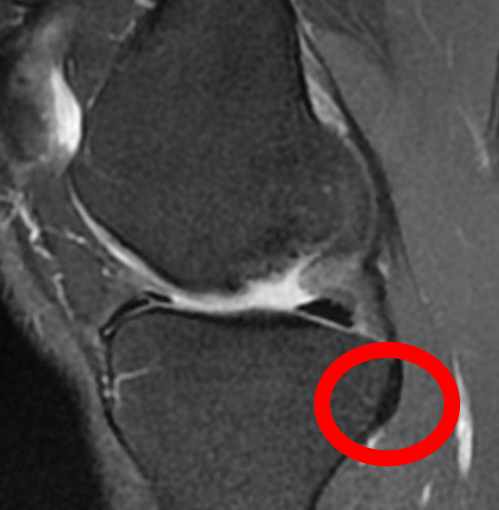Guide pin for the PCL tunnel



Retro-drilling drill for posterolateral reconstruction

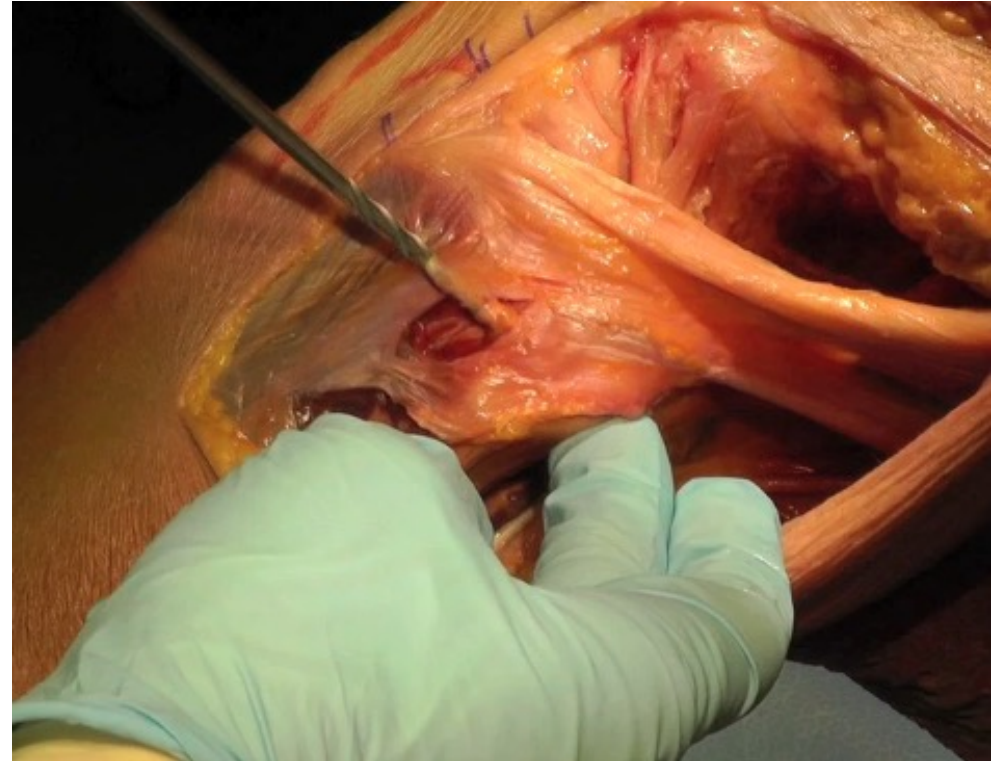


Expose the postero lateral part
of the proximal tibia

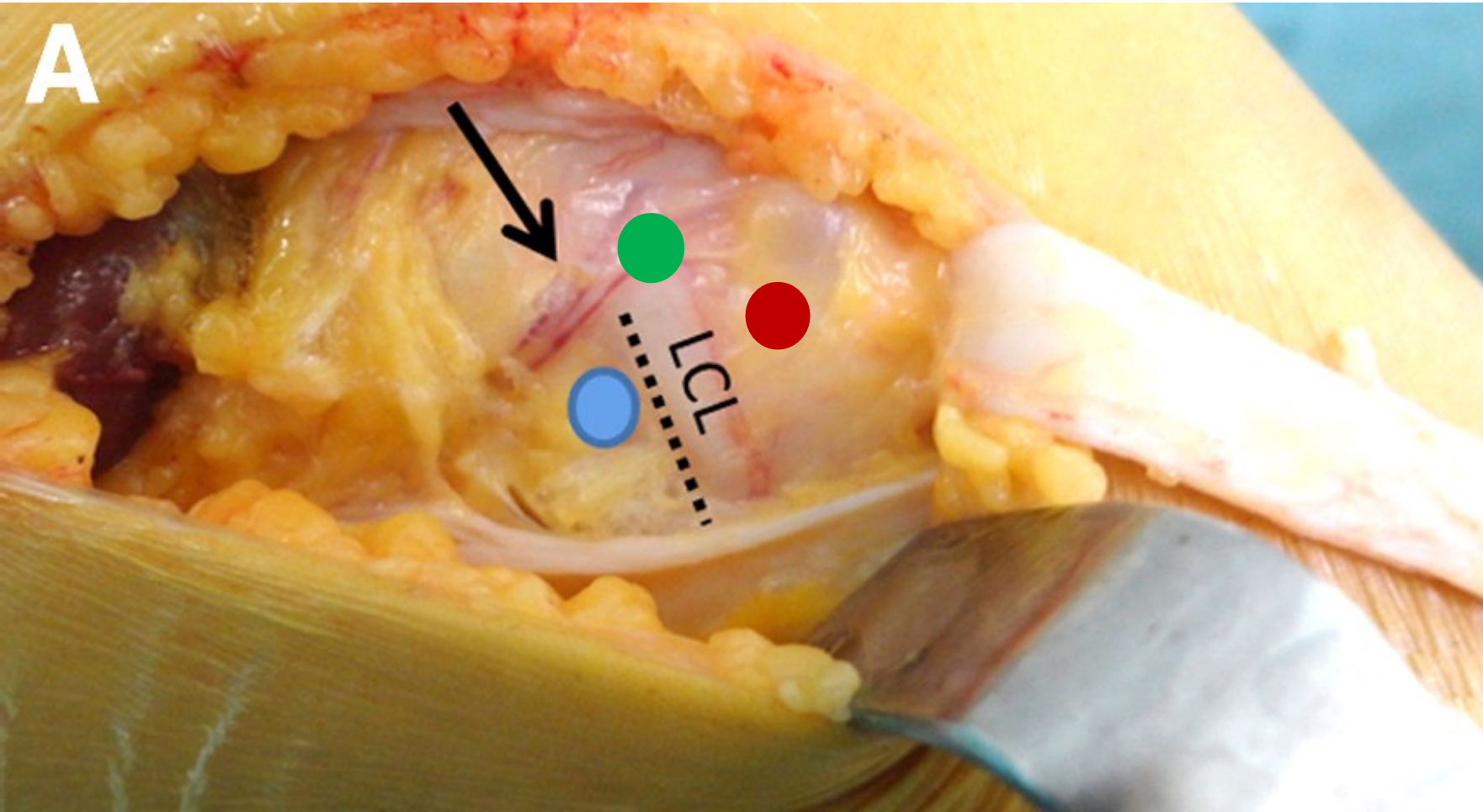


SECONDLY FIBULAR TUNNEL

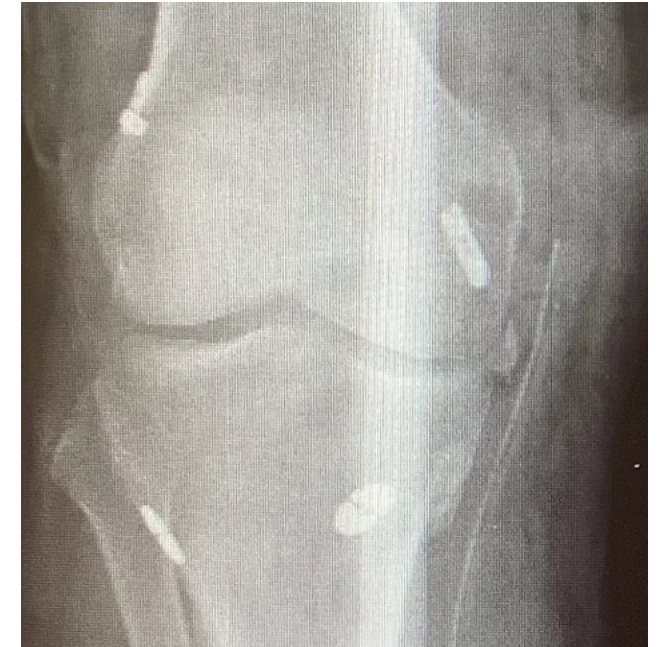- Creation of the fibular tunnel
- Passage of the ST into the fibular tunnel
- Creation of the femoral tunnel
- Fixation of the plasty in the femoral tunnel
- Suturing the residual stumps on the graft
- Closing



THIRDLY: FEMORAL TUNNELS



- ACL
- FCL
- Popliteus



3 tunnels in a small area

Fixation

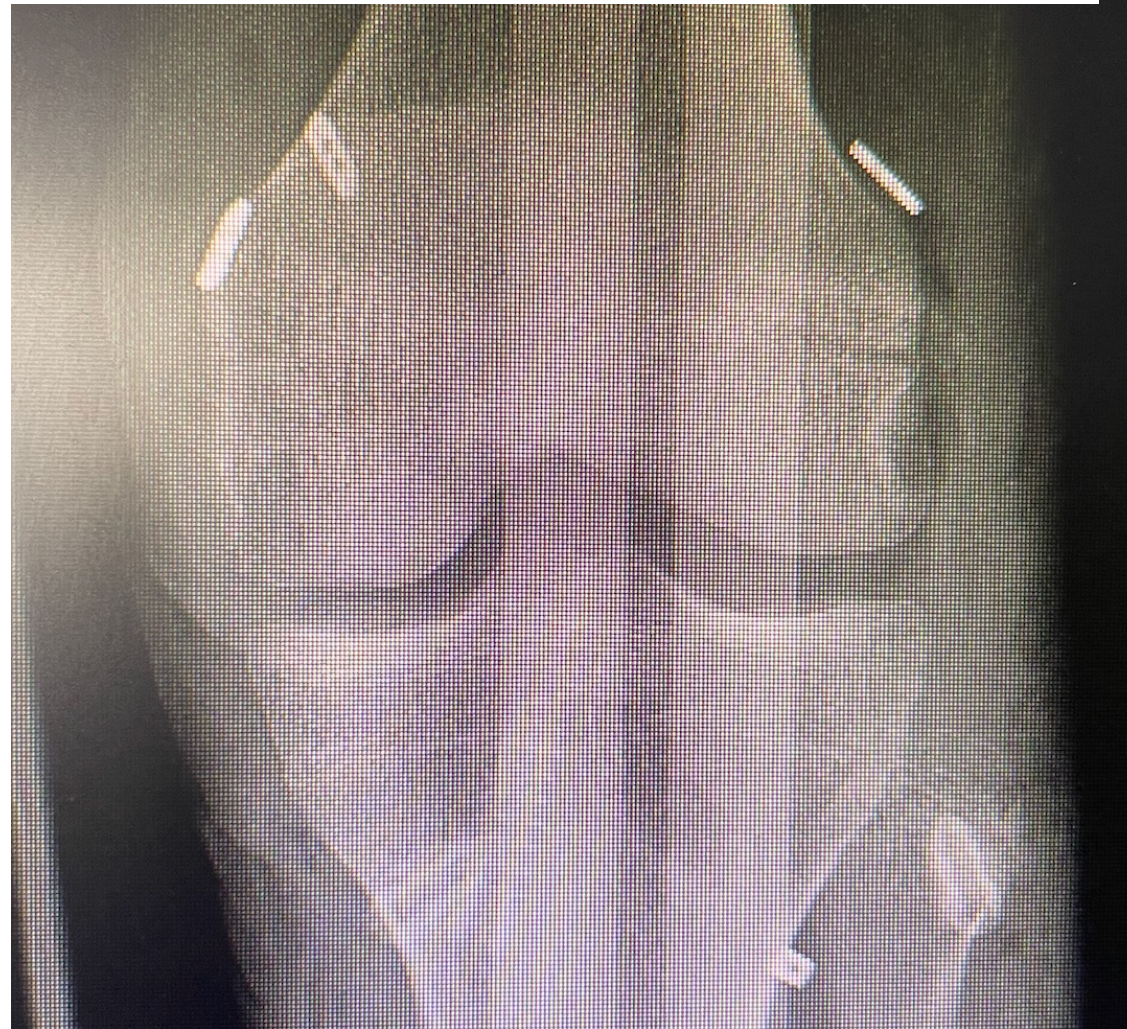
THEN FIXATION

Fixation

1-Tibial endobouton

2- Femoral fixation of the FCL (extension and valgus)

3- Popliteal tendon
External rotation and 60° flexion



3

1

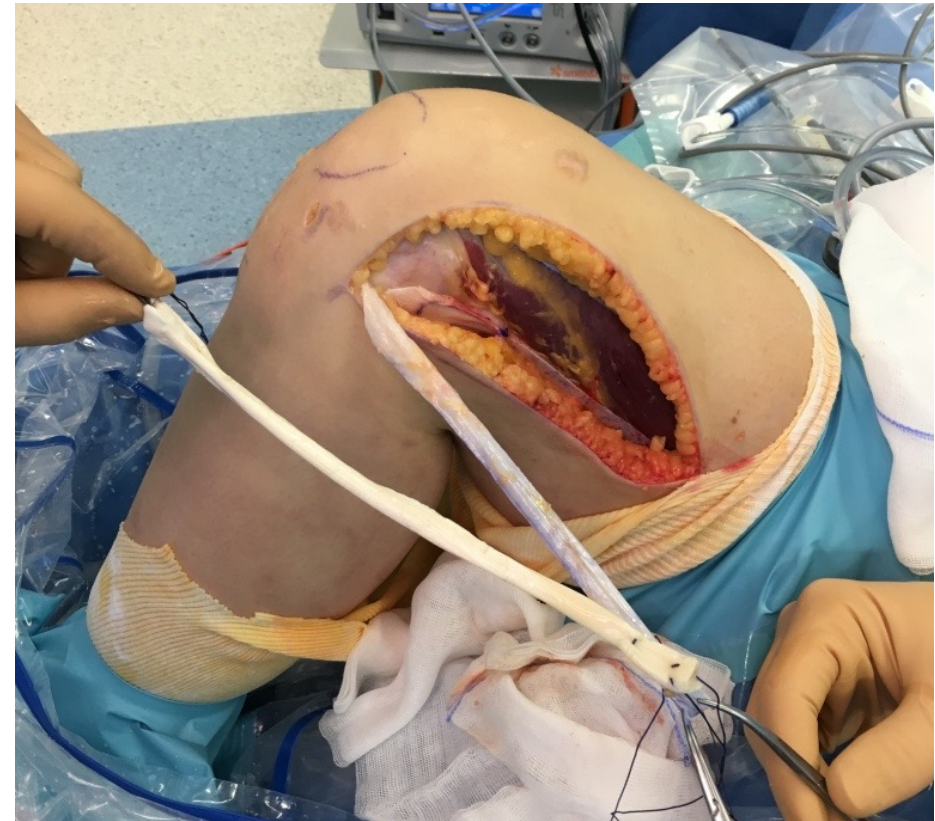
2

The popliteal beam is shorter (4 to 6 cm)

The FCL beam is longer (7 to 9 cm)


tips and tricks

- Increase the diameter of the ACL plasty with a hamstring or allograft
- Allows you to reduce the width of the fascia (simpler closure)

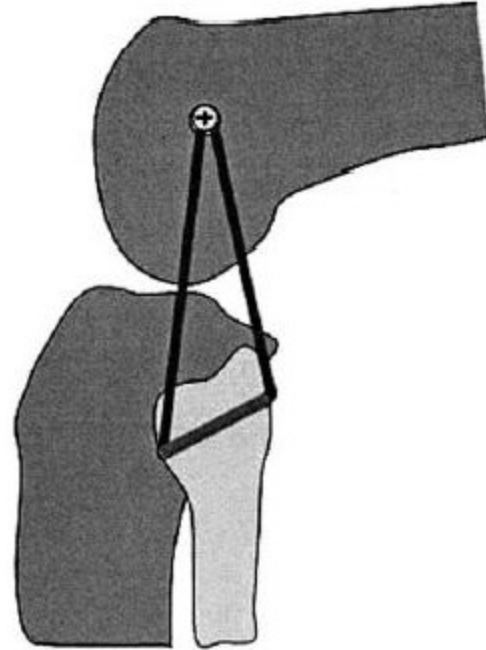


tips and tricks

longitudinal fasciotomy of posterior compartment of thigh
Allows sliding and lateral translation of the fascia



tips and tricks



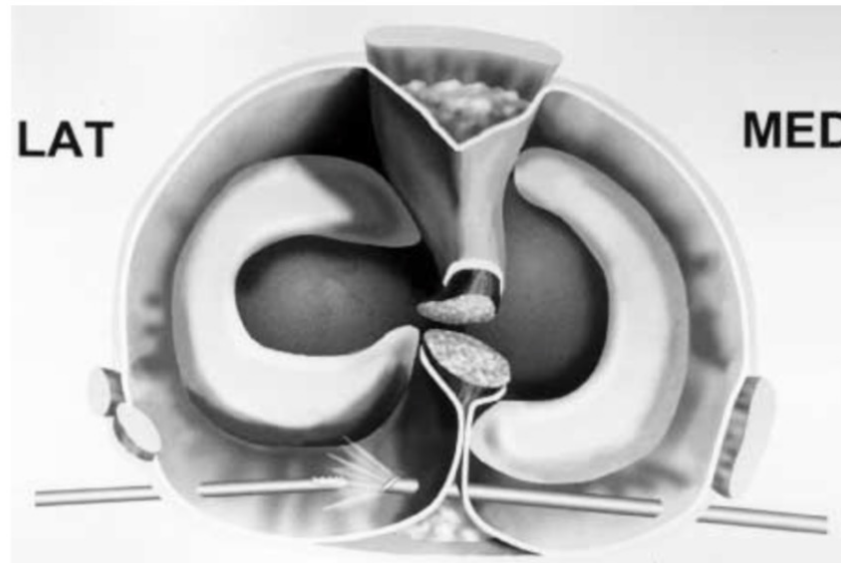
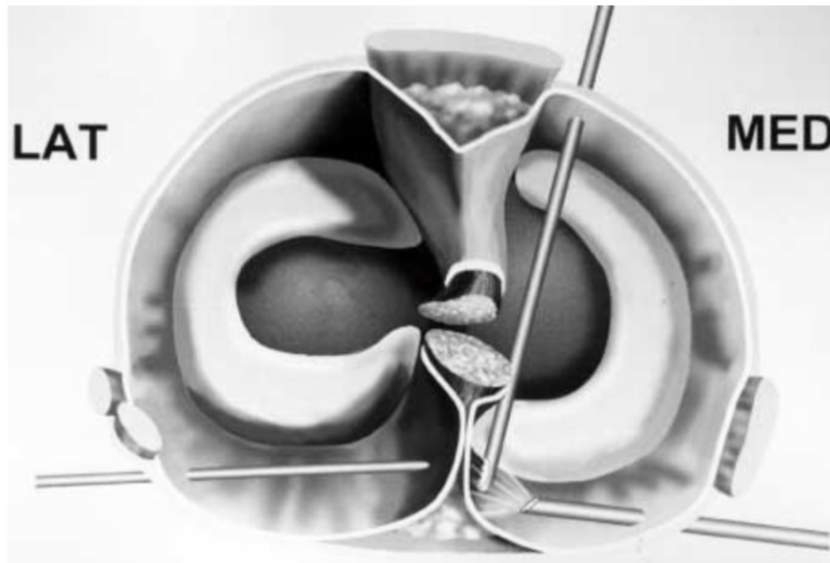
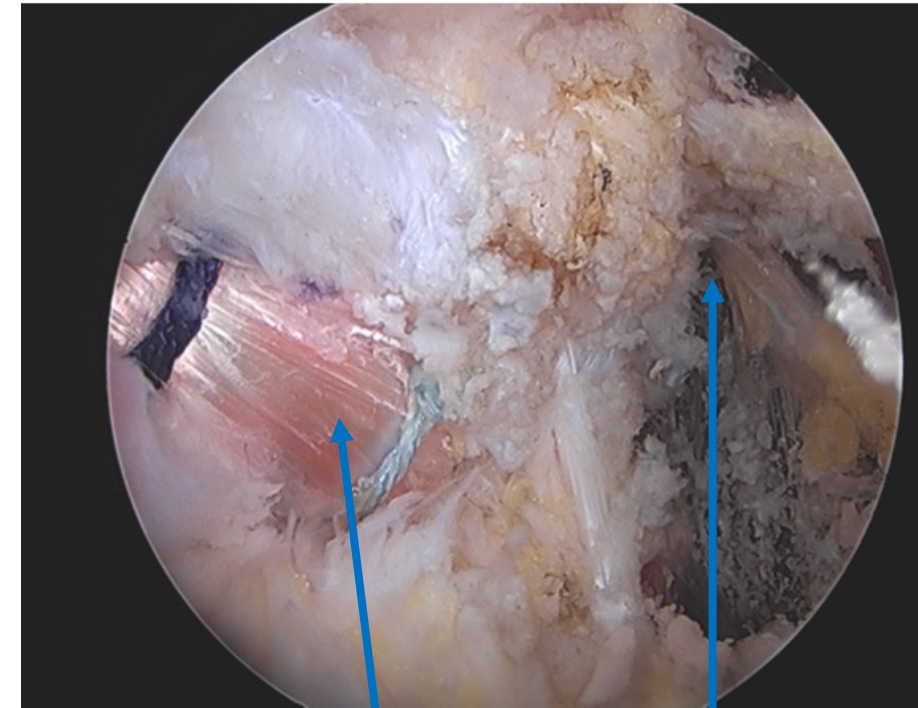
« Small knee »: one femoral tunnel (Larson)

tips and tricks

Posterior Arthroscopic Approach

Posterior Trans-Septal Portal for Arthroscopic Surgery of the Knee Joint

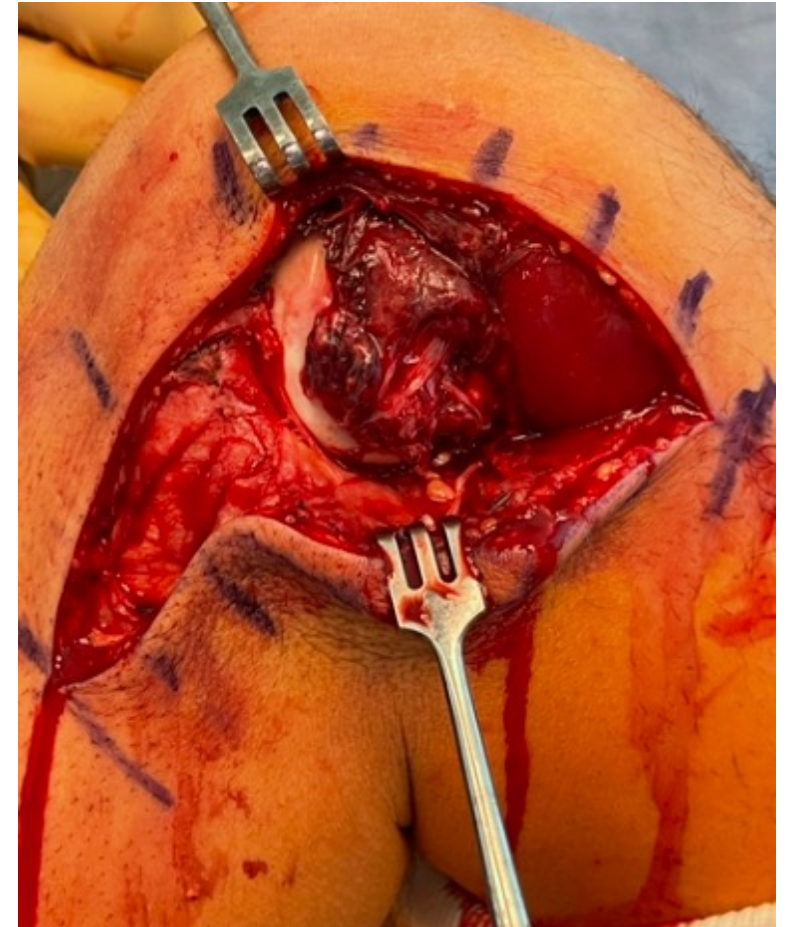
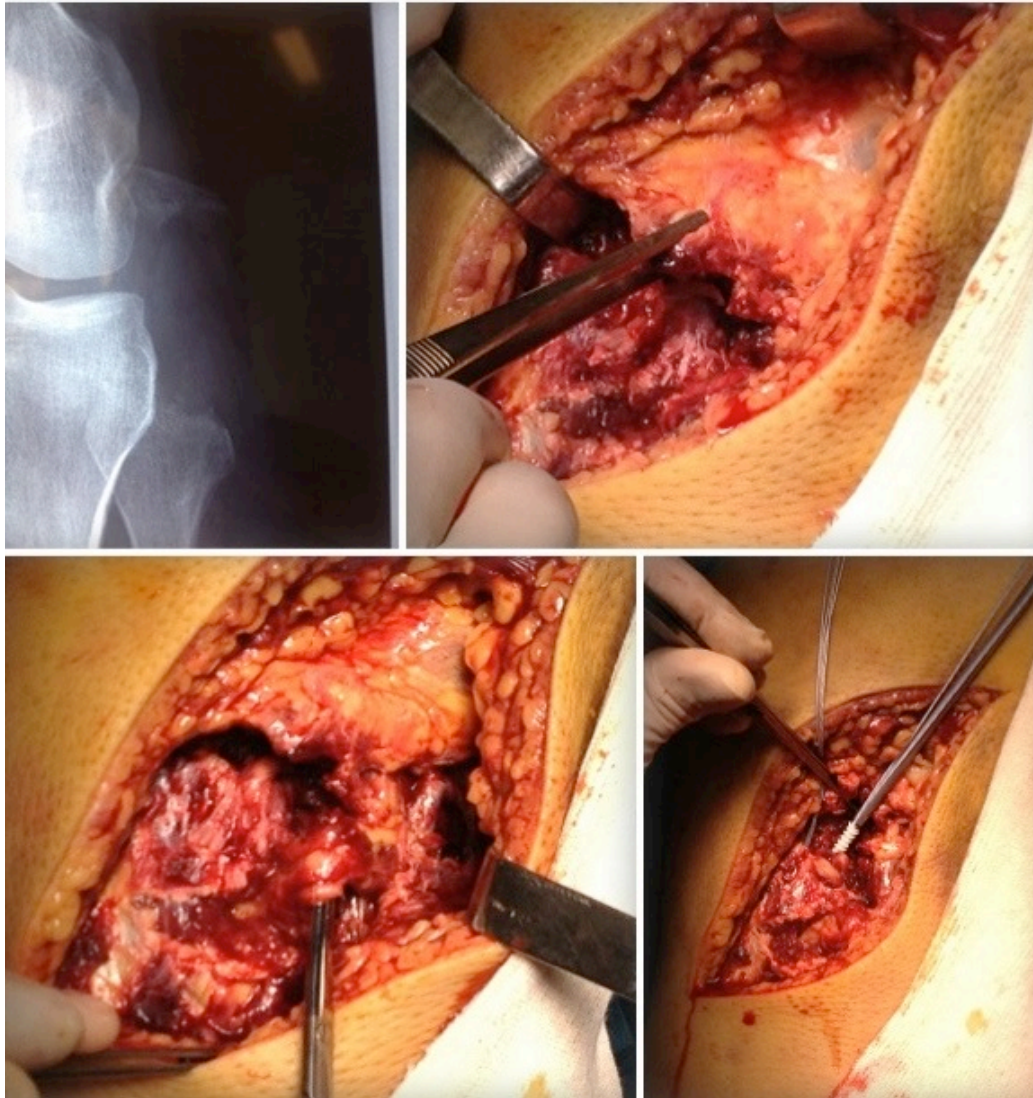
Jin-Hwan Ahn, M.D., and Chul Won Ha, M.D.



PCL

Tibial tunnel for
postero-lateral
reconstruction

BUT OFENTLY FOR ACUTE CASE...



Keys points

- Don't miss the diagnosis
- Difficult surgery
- Lateral approach;
 - ACL + ALL reconstruction
 - Large view on the posterior structure
- Graft >> Suture
- Allograft = Autograft

